

# A Method for Automated Segmentation of the Stomach and its Application for Navigated Diagnosis

Ryosuke KONO<sup>a</sup>, Yoshito MEKADA<sup>b,\*</sup>, Kensaku MORI<sup>a</sup>,  
Ichiro IDE<sup>a</sup>, Hiroshi MURASE<sup>a</sup>, Jun-ichi HASEGAWA<sup>b</sup>,  
Shigeru NAWANO<sup>c</sup>

<sup>a</sup>Graduate School of Information Science, Nagoya University

<sup>b</sup>School of Life System Science and Technology, Chukyo University

<sup>c</sup>National Cancer Center Hospital East

---

**Abstract.** In this paper, we propose a method for automated segmentation of gastric segment named Stomap from 3D abdominal X-ray CT images and its application for the navigation-based diagnosis system. The gastric segment enables us to recognize the position in stomach while diagnosing stomach using virtualized endoscope system. It can also be utilized as a criterion of the appropriateness of navigation path. The number of observed time for each segment based on the gastric segment is proposed for the evaluation of navigation path. The result showed that the distribution of observation time and the shape of navigation path correlated each other.

*Keywords:* Virtualized Endoscope System ; 3D abdominal X-ray CT; Gastric Segment

---

## 1. Introduction

In this paper, we propose a method for automated segmentation of gastric segments from 3-D abdominal X-ray CT images and its application for a virtualized gastroscopie diagnosis system.

Recently, diagnosis using the Virtualized Endoscope System (VES) has been widely applied for detecting cancers in their early stages[1,2,3]. In some Japanese hospitals, a virtualized gastroscopie is available as an option in a thorough medical examination. However, observing complex organs efficiently is difficult and sets a heavy burden on medical doctors; therefore, automatic generation of navigation environments, which includes generation of navigation paths, presentation of observed regions through VES diagnosis, and confirmation of a suspicious region detected by a computer-aided diagnosis (CAD) system, is required. The purpose of this study is to improve the effectiveness of navigating around the stomach's inner environment based on automated segmentation of the gastric inner surface according to a gastric segment map named Stomap(**Fig. 1**). Stomap is often used in Japan to define anatomical positions on the gastric inner surface.

---

\* Corresponding author. [y-mekada@life.chukyo-u.ac.jp](mailto:y-mekada@life.chukyo-u.ac.jp)

## 2. Method

In the proposed method, we segment the gastric inner surface, which is detected from 3-D X-ray CT abdominal images in accordance with Stomap. Each Stomap segment of is defined on the resected stomach. The stomach surface is divided into eight regions along the greater curvature and the lesser curvature (horizontal direction), and each segment is further divided into ten regions in the orientation perpendicular to the horizontal direction (vertical direction). As an exception, the fundus of the stomach is segmented into seven segments; therefore, in total there are 77 segments. Each region is named systematically such as “Body on Posterior near Greater Curvature,” “Pyloric Antrum on Lesser Curvature,” etc. Below, we describe a method to realize Stomap in 3-D of the gastric inner surface.

### 2.1 Preparation

To realize a Stomap of the gastric inner surface, we specify four important anatomical points, which are (P1) top of the fundus, (P2) top of the pre-pyloric, (P3) cardiac part on the lesser curvature, and (P4) cardiac part on the greater curvature(Fig. 1).

### 2.2 Segmentation method

#### (a) Determination of division points

A method to determine the division points that define the boundary of each region is described in this section. First, a projection image is made by projecting the gastric inner surface from the ventral side to the dorsal side. Next, division points on the greater curvature and the lesser curvature are determined as points that divide each curvature line (from P3 to P2 and from P4 to P2) into seven equal parts. The other points are determined according to the Stomap so as to divide the lines perpendicular to the greater curvature and the lesser curvature into ten parts by the ratio of 6:6:6:6:2:2:2:6:6:6.

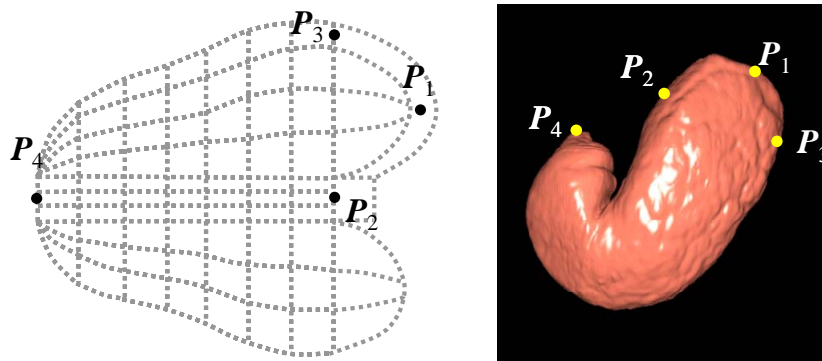


Fig.1 Stomap(left) and inputted division points on the stomach wall.

(b) Assignment of names to the Stomap segments

To assign each Stomap segment onto the stomach surface, first, the input region of the gastric inner surface is separated off by using the boundary lines defined by roughly connecting the division points. Second, the distance between each center of gravity of the separated region and each center of gravity of division points that compose the Stomap segment are calculated. Then, the anatomical name of each region is assigned to the nearest segment.

### **3. Application for VES**

To apply Stomap to a navigated diagnosis system, we implemented the following three functions.

#### *3.1 Display the name of a Stomap segment*

In diagnosis using VES, observed regions are sometimes difficult to recognize. Therefore, we displayed the boundaries of Stomap segments and their names on the VES. A user could easily turn this function on and off during navigation. We consider that the observed regions become easier to recognize as a result.

#### *3.2 Evaluation of navigation paths*

It is important to diagnose all areas of the gastric inner surface during VES diagnosis. However, in most cases some regions are missed after the navigation. To identify such regions in order to minimize oversights, we check the number of times for each region displayed during navigation. The number of times each Stomap segment is displayed adds up only if the distance between the viewpoint and the gastric inner surface is smaller than the predefined threshold. The results were visualized by mapping them onto the Stomap.

#### *3.3 Automatic generation of navigation paths*

In a case when there are suspicious regions, such as locations detected by the CAD system that appear to be candidates for cancer, the navigated diagnosis should observe them appropriately. We propose a method to generate navigation paths to carefully examine such regions, where the viewing position of the proposed navigation path is on the medial axis of the stomach and the viewing direction is tangential to it. The viewing position and direction can be changed smoothly toward the region under suspicion until the distance between the region and the navigation path meets predefined conditions.

## **4. Results**

### *4.1 Stomap Generation*

We applied the proposed method to ten cases of gastric inner surfaces detected from 3-D CT images. In all cases, segmentation results were acceptable except for the pylorus

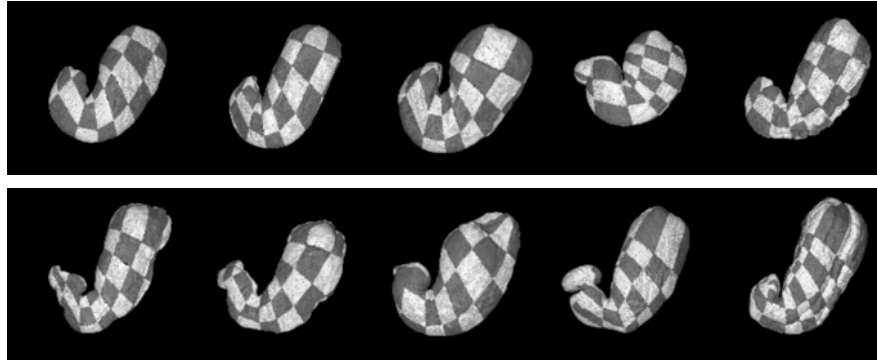


Fig.2 Segmentation results.

part(**Fig.2**). In four cases, all of the segmentation results were sufficient. There were some slight mis-segmentations at the pylorus part in three cases. In the remaining cases, some undesirable segmentations occurred, such as enclaves and segments that were too small, since the pylorus part of these cases was too complicated in shape to define the border, or the distance between the incisura and the pylorus was relatively long. Most of the errors occurred between the incisura and the pylorus.

#### 4.2 Applications for VES

Using the proposed navigation options, it was easy to recognize the anatomical location of the observed area during navigated diagnosis(**Fig.3**). It was also a simple matter to recognize the observed and unobserved areas after the navigated diagnosis(**Fig.4**). As for the automated generation of the navigation path, it was important to check the region under suspicion precisely by generating various view directions and by the interactive observation environment.

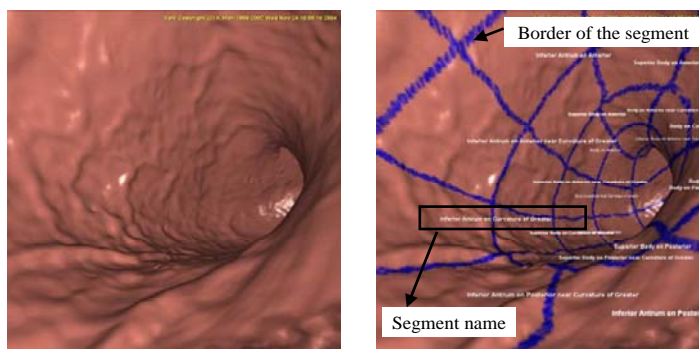


Fig.3 (Left) VES image. (Right) Displaying the name of Stomap segments and their border on VES.

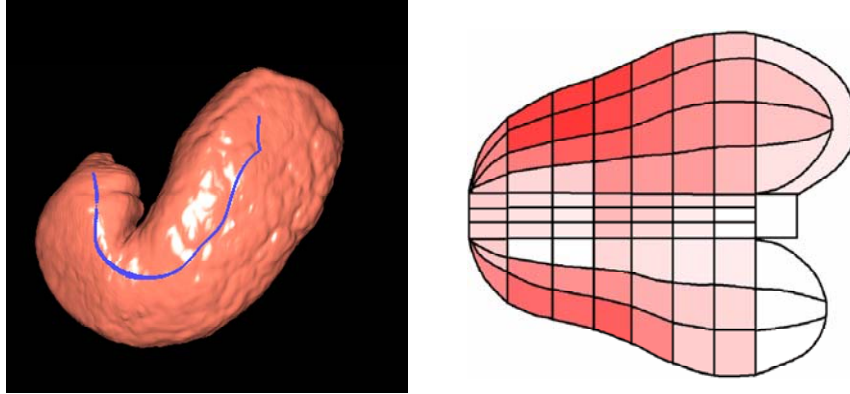


Fig.4 Navigation path(Left) and the result of the observed and unobserved areas(Right). Brighter parts correspond to the areas displayed very few.

## 5. Conclusion

In this paper, we proposed a method for segmenting a gastric segment map named Stomap, and application of it to assist a navigated diagnosis. We applied the proposed method to ten cases of 3-D abdominal X-ray CT images. To realize Stomap in three dimensions, the proposed method defines the borders between segments according to Stomap's own definitions. In order to assist navigated diagnosis, we embedded three navigation options, indicating the segment name and its border for assistance during navigation, an evaluation criterion for the navigation path concerning indication times throughout the navigation, and automated generation of a navigation path to examine suspicious regions. The experimental results indicated that the proposed method could partition a gastric inner surface adequately, except for the pylorus region, and was useful for assisting navigated diagnoses.

Future works include improving segmentation accuracy and automated generation of the optimal navigation path.

## References

- [1] Yuuichiro Hayashi, Kensaku Mori, Jun-ichi Hasegawa, et al., Quantitative evaluation of observation methods in virtual endoscopy based on the rate of undisplayed region, Proc. of SPIE, Medical Imaging 2003, Physiology and Function : Methods, Systems, and Applications, 2003;69-79
- [2] Martina M. Morrin, and J. Thomas LaMont, Screening Virtual Colonoscopy — Ready for Prime Time?, New England Journal of Medicine, 2003, 23, 349; 2261-2264
- [3] Fenlon HM, Nunes DP, Schroy PC III, Barish MA, Clarke PD, Ferrucci JT. A comparison of virtual and conventional colonoscopy for the detection of colorectal polyps. N Engl J Med 1999;341:1496-1503